

Advanced thymic carcinoma showing a stable disease reaction to single-agent amrubicin as a third-line chemotherapy: case report

Satoshi Igawa,¹ Nobuyuki Yanagisawa,² Sachiyo Maki,¹ Sakiko Otani,¹ Yasuhiro Hiyoshi,¹
Michiko Kimura,¹ Masashi Kasajima,¹ Mikiko Ishihara,¹ Nobuatsu Hayashi,¹
Yujiro Nagashima,¹ Noriyuki Masuda¹

¹Department of Respiratory Medicine, Kitasato University School of Medicine

²Department of Pathology, Kitasato University School of Medicine

Thymic carcinoma is a rare but aggressive thymic neoplasm. The optimal regimen of chemotherapy for thymic carcinoma in the second and subsequent lines of therapy remains unclear. We report a case of a patient with thymic carcinoma who showed a response of stable disease to third-line chemotherapy with single-agent amrubicin (AMR), a synthetic anthracycline analogue and potent DNA topoisomerase II inhibitor. A 57-year-old man was diagnosed with thymic carcinoma complicated by pleural dissemination and pulmonary metastasis. When a recurrence was diagnosed after CODE (cisplatin, vincristine, doxorubicin, etoposide) combination chemotherapy and subsequent carboplatin (CBDCA) plus paclitaxel combination chemotherapy as a second-line therapy, AMR was administered as a 5-minute intravenous infusion at a dose of 40 mg/m² daily on three consecutive days, every 3 weeks. Four cycles of AMR were administered, and stable disease was confirmed. There were no severe hematological or non-hematological toxicities. It was concluded that AMR can be an effective therapeutic option for advanced thymic carcinoma. To our knowledge this is the first report to demonstrate an activity of AMR against thymic carcinoma in a third-line setting.

Key words: thymic carcinoma, chemotherapy, third-line, amrubicin

Introduction

Thymic carcinoma is a rare, invasive mediastinal neoplasm that has a high propensity for metastasis. Because of its rare occurrence, only limited numbers of patients have been analyzed in studies published thus far. The extent of disease at presentation often precludes complete surgical resection, and systemic chemotherapy plays a very important role in treatment. The optimal treatment for unresectable thymic carcinoma remains unclear, and the efficacy of second-line and further treatment is also still unclear. We report a case of a patient with advanced thymic carcinoma that had progressed after two prior chemotherapy regimens who was successfully treated with amrubicin (AMR) administered as a single agent.

Case Report

A 57-year-old man who had undergone total thymectomy

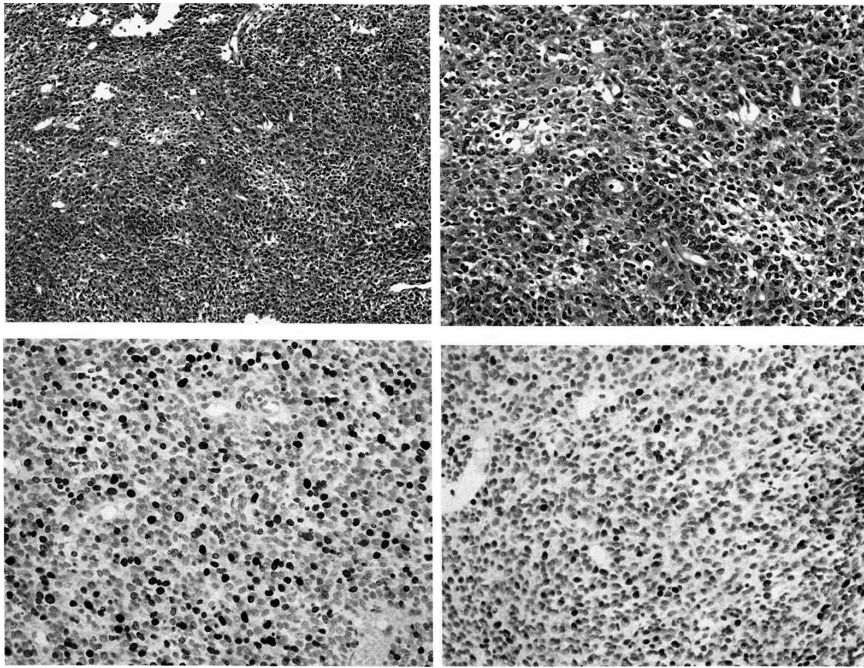
for thymic carcinoma at another hospital in 2005 was admitted to our hospital in 2009 because of increasing chest discomfort and abnormal shadows in the right lung on a chest x-ray. Computed tomography (CT) of the chest revealed pleural dissemination and a lung metastasis in the right lung. CT-guided percutaneous needle-biopsy of the pleural dissemination yielded small tissue fragments, and histological examination revealed a highly cellular tumor composed of epithelioid cells that exhibited nuclear atypia and contained eosinophilic cytoplasm (Figure 1A, B). Some rosette-like structures and remnant perivascular spaces were also seen, and uniform infiltration by a few lymphoid cell was evident throughout the tumor, but there was no overt keratinization. Immunoreactivity for CD5 was detected partially in tumor cells; but immunostaining for CD117 and neuroendocrine markers, including chromogranin A and synaptophysin, was negative. The tumor cells had a high MIB-1 labeling index (approximately 25%, Figure 1C),¹ and sporadic *p53* protein overexpression was observed (Figure 1D).

Received 23 May 2011, accepted 22 June 2011

Correspondence to: Satoshi Igawa, Department of Respiratory Medicine, Kitasato University School of Medicine

1-15-1 Kitasato, Minami-ku, Sagami-hara, Kanagawa 252-0374, Japan

E-mail: igawa@kitasato-u.ac.jp

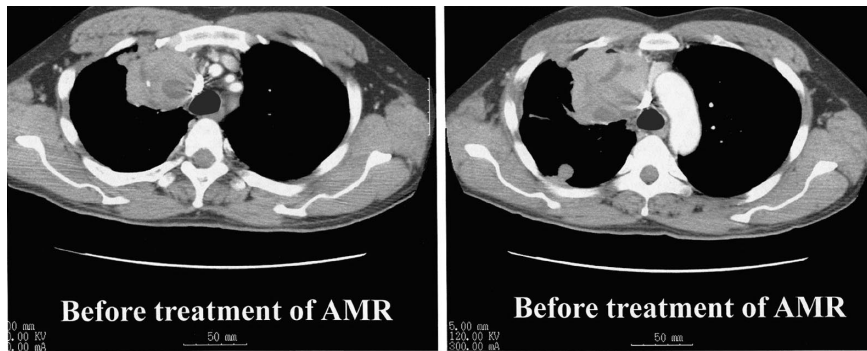


A, B. Hematoxylin-eosin-stained section of the highly cellular tumor composed of epithelioid cells (original magnification: **A**, $\times 100$; **B**, $\times 200$).

| | |
|----------|----------|
| A | B |
| C | D |

C, D. The tumor cells had a high MIB-1 labeling index and (**D**) exhibited sporadic *p53* overexpression (original magnification: **C, D**, $\times 200$).

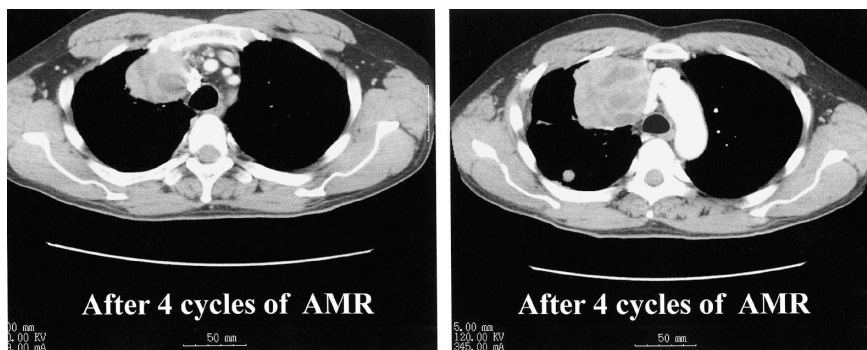
Figure 1



A

B

Figure 2. **A.** The CT scans of the chest in May 2010 revealed re-growth of pleural dissemination and **B.** pulmonary metastasis.



A

B

Figure 3. The CT scans of the chest in September 2010 after 4 cycles of chemotherapy showed: **A.** reduction in the size of the pleural dissemination and **B.** the pulmonary metastasis.

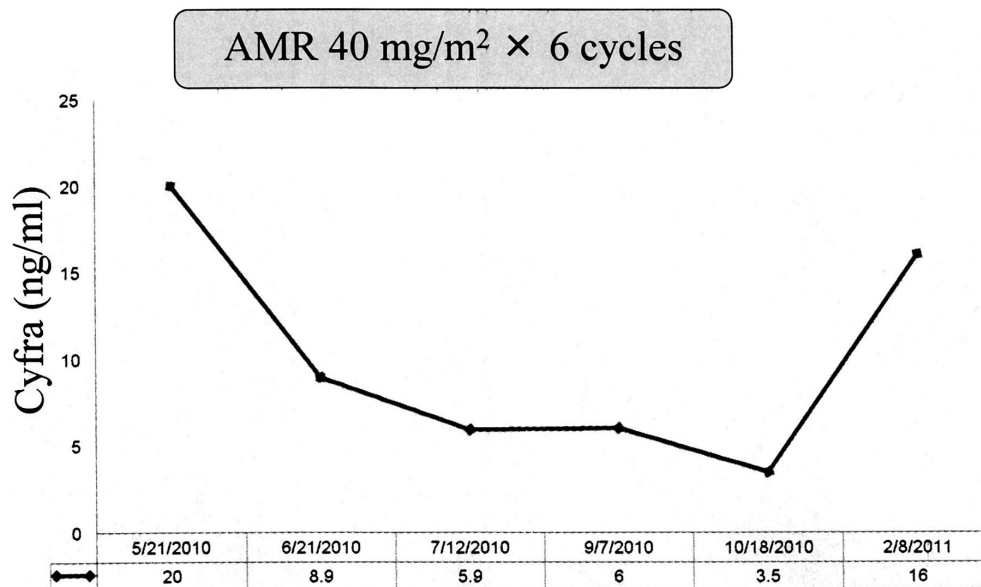


Figure 4. Changes in the serum Cyfra level

These findings were consistent with thymic carcinoma, and a diagnosis of postoperative metastatic thymic carcinoma, stage IVB (according to the classification proposed by Masaoka²) was made.

The patient was treated with cisplatin, vincristine, doxorubicin, and etoposide (CODE) combination chemotherapy in the first-line setting, and he showed a partial response. After a recurrence of CODE he was treated with four cycles of carboplatin plus paclitaxel, and he achieved disease control. However, the CT scans of the chest in May 2010 revealed re-growth of both the pleural dissemination and the pulmonary metastasis (Figure 2A, B), and the serum Cyfra level was elevated to 20 ng/ml. The institutional upper limit of normal value of serum Cyfra is 3.5 ng/ml. A single-agent amrubicin (AMR) therapy in the third-line setting was begun in May 2010 and consisted of intravenous infusion of AMR in 50 ml of normal saline over 5-minutes at a dose of 40 mg/m² per day on days 1-3 every 3 weeks, and four cycles of the AMR therapy were administered. The response was evaluated in accordance with Response Evaluation Criteria in Solid Tumors version 1.1.³ CT scans of the chest in September 2010 after 4 cycles of AMR showed a 12% decrease in the sum of diameters of target lesions comparing with the baseline sum of diameters, indicating confirmed SD (Figure 3A, B). After two additional cycles of AMR, the serum Cyfra level had decreased to an institutional upper limit of normal value (Figure 4). All cycles of AMR were administered without dose reduction (total dose, 402 mg/body). The adverse events related to AMR administration were evaluated according to the Common Toxicity Criteria for Adverse

Events, Version 4.0 grading system proposed by the National Cancer Institute. The hematological toxicities that occurred were grade 3 neutropenia and grade 1 leukopenia and no severe nonhematologic toxicities including febrile neutropenia. Afterward, CT scans of the chest in February 2011 unfortunately revealed re-growth of the pleural dissemination and the pulmonary metastasis, an increase in the serum Cyfra level was observed (Figure 4), and the progression-free survival time (PFS) of this patient was 8.5 months. After the confirmation of the progressive disease, the patient has been receiving the best supportive care as an outpatient. In June 2011, as of this writing, the patient is still alive.

Discussion

Since several reports have indicated the efficacy of combination chemotherapy regimens containing cisplatin and doxorubicin, such as ADOC (cisplatin, doxorubicin, vincristine, and cyclophosphamide) and CODE, as treatment for thymic carcinoma,^{4,5} doxorubicin is an anthracycline, an antitumor agent that is a highly reliable agent for the treatment of thymic carcinoma. Nonetheless, the optimal treatment for thymic carcinoma remains unclear, and the efficacy of second-line or more settings also remains unclear. The present report is of a patient with advanced thymic carcinoma who experienced relapses after two prior regimens and acquired a period of disease control and PFS of 8.5 months with a single-agent of AMR.

In Japan, AMR was developed for the treatment of small cell lung cancer (SCLC), and non-small cell lung

cancer (NSCLC). In the first-line setting, a platinum doublet regimen containing AMR showed an overall response rate (ORR) of 76% in the patients with SCLC,⁶ and of 18%-28% in patients with NSCLC.^{7,8} In the second-line setting AMR monotherapy yielded an ORR of 17%-52% in the patients with SCLC,^{9,10} and of 12% in the patients with NSCLC.¹¹ These results suggest that AMR is recognized as a promising anticancer agent for lung cancer.

To the best of our knowledge, the present report is the first to suggest the activity of AMR against advanced thymic carcinoma in the third-line setting. AMR is a totally synthetic anthracycline and a potent topoisomerase II inhibitor. Moreover, AMR has been shown to have an antitumor effect that is greater than that of doxorubicin in an experimental animal model.¹² AMR and its 13-hydroxy metabolite amrubicinol have been shown to inhibit the enzyme activity of purified human DNA topoisomerase II.¹³ Amrubicinol is 10-100 times more cytotoxic than AMR.¹⁴ Thus, AMR activity against advanced thymic carcinoma is greater than that of doxorubicin. Certainly a cardiotoxicity has been particularly recognized as a principle toxicity of doxorubicin, but AMR did not exhibit any potential for chronic cardiotoxicity in an experimental animal model.¹⁵ Cardiotoxicity was not observed in the present case.

In conclusion, thymic carcinoma can be expected to show a clinical response to chemotherapy with AMR. Because of the activity of single-agent AMR against thymic carcinoma, further studies of this agent either as a single agent or in combination with other agents are warranted.

References

1. Comin CE, Messerini L, Novelli L, et al. KI-67 antigen expression predicts survival and correlates with histologic subtype in the WHO classification of thymic epithelial tumors. *Int J Surg Pathol* 2004; 12: 395-400.
2. Masaoka A, Monden Y, Nakahara K, et al. Follow-up study of thymomas with special reference to their clinical stages. *Cancer* 1981; 8: 2485-92.
3. Eisenhauer EA, Therasse P, et al. New response evaluation criteria in solid tumours: revised RECIST guideline (version 1.1). *Eur J Cancer* 2009; 45: 228-47.
4. Koizumi T, Takabayashi Y, Yamagishi S, et al. Chemotherapy for advanced thymic carcinoma: clinical response to cisplatin, doxorubicin, vincristine, and cyclophosphamide (ADOC chemotherapy). *Am J Clin Oncol* 2002; 25: 266-8.
5. Yoh K, Goto K, Ishii G, et al. Weekly chemotherapy with cisplatin, vincristine, doxorubicin, and etoposide is an effective treatment for advanced thymic carcinoma. *Cancer* 2003; 98: 926-31.
6. Yana T, Negoro S, Takada M, et al. Phase II study of amrubicin in previously untreated patients with extensive-disease small cell lung cancer: West Japan Thoracic Oncology Group (WJTOG) study. *Invest New Drugs* 2007; 25: 253-8.
7. Sawa T, Yana T, Takada M, et al. Multicenter phase II study of amrubicin, 9-amino-anthracycline, in patients with advanced non-small-cell lung cancer (Study 1): West Japan Thoracic Oncology Group (WJTOG) trial. *Invest New Drugs* 2006; 24: 151-8.
8. Takeda K, Takifuji N, Negoro S, et al. Phase II study of amrubicin, 9-amino-anthracycline, in patients with advanced non-small-cell lung cancer: a West Japan Thoracic Oncology Group (WJTOG) study. *Invest New Drugs* 2007; 25: 377-83.
9. Onoda S, Masuda N, Seto T, et al. Phase II trial of amrubicin for treatment of refractory or relapsed small-cell lung cancer: Thoracic Oncology Research Group Study 0301. *J Clin Oncol* 2006; 24: 5448-53.
10. Inoue A, Sugawara S, Yamazaki K, et al. Randomized phase II trial comparing amrubicin with topotecan in patients with previously treated small-cell lung cancer: North Japan Lung Cancer Study Group Trial 0402. *J Clin Oncol* 2008; 26: 5401-6.
11. Kaneda H, Okamoto I, Hayashi H, et al. Phase II trial of amrubicin for second-line treatment of advanced non-small cell lung cancer: results of the West Japan Thoracic Oncology Group trial (WJTOG0401). *J Thorac Oncol* 2010; 5: 105-9.
12. Yamaoka T, Hanada M, Ichii S et al. Cytotoxicity of amrubicin, a novel 9-aminoanthracycline, and its active metabolite amrubicinol on human tumor cells. *Jpn J Cancer Res* 1998; 89: 1067-73.
13. Hanada M, Mizuno S, Fukushima A, et al. A new antitumor agent amrubicin induces cell growth inhibition by stabilizing topoisomerase II-DNA complex. *Jpn J Cancer Res* 1998; 89: 1229-38.
14. Noguchi T, Ichii S, Morisada S, et al. Tumor-selective distribution of an active metabolite of the 9-aminoanthracycline amrubicin. *Jpn J Cancer Res* 1998; 89: 1061-6.
15. Noda T, Watanabe T, Kohda A. Chronic effect of a novel synthetic anthracycline derivative (SM-5887) on normal heart and doxorubicin-induced cardiomyopathy in beagle dogs. *Invest New Drug* 1998; 16: 121-8.